

**PADRE PIO WITH HIS BROTHER MICHELE**

**(AS YOU CAN SEE IN THE PICTURE PADRE PIO'S FEET  
ARE QUITE SWOLLEN FROM HIS WOUNDS)**

**FOR MORE STORIES ABOUT PDRE PIO  
PLEASE VISIT THE WEBSITE: [www.pamphletstoinspire.com](http://www.pamphletstoinspire.com)**

**Padre Pio's  
X-RAYS  
of his  
Hands and Feet**

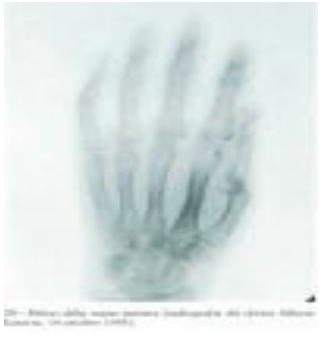

***"NOT ONE OF HIS BONES WILL BE BROKEN"***

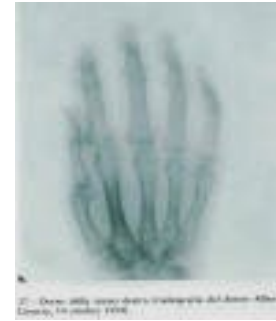
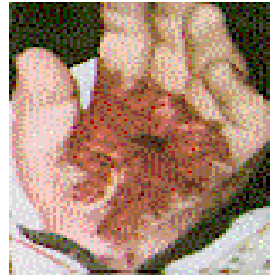**JOHN 19: 36**

Dr. Alberto Caserta of Foggia did x-rays of the hands of Padre Pio on October 13, 1954. The radiographs did not show interruptions in the bones

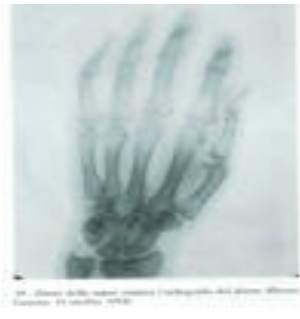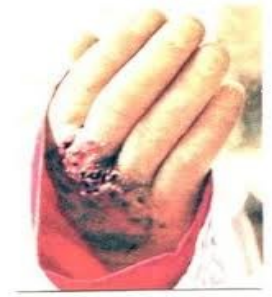## X-Rays



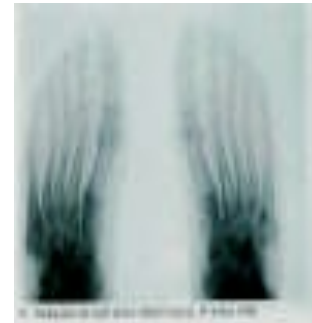
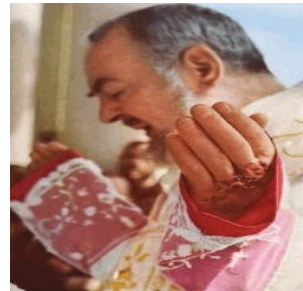
Palm of left hand




Back of right hand



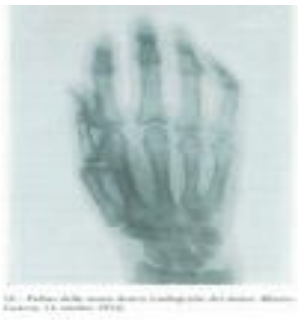Back of left hand



Feet



No known pictures of his bare Feet.



Palm of right hand



In 1954 Padre Pio had not been feeling well, with respiratory problems. Prof. Francesco Lotti testified: "On October 13, 1954, with the superior of the convent Padre Carmelo da Sessano, we took Padre Pio to the radiology department of Casa Sollievo to have an x-ray of the head and chest done. By disposition of Padre Carmelo, and without Padre Pio knowing it, we did also radiographs of hands and feet. I was told by the radiologist that there was absolutely nothing abnormal at the level of the metacarpal and metatarsal areas."

*(Gerardo, Le Stigmate 1985, 300-3)*

*(Ger85, Appendice fotografica, 17-21)*